




Contents lists available at ScienceDirect

## European Journal of Surgical Oncology

journal homepage: [www.ejso.com](http://www.ejso.com)

## Preoperative breast MRI in management of patients with needle biopsy-proven ductal carcinoma in situ (DCIS)

Sara van Bekkum<sup>a</sup>, Bert P.M. ter Braak<sup>b</sup>, Peter W. Plaisier<sup>a</sup>, Joost van Rosmalen<sup>c</sup>, Marian B.E. Menke-Pluijmers<sup>a</sup>, Pieter J. Westenend<sup>d, e, \*</sup>

<sup>a</sup> Department of Surgery, Albert Schweitzer Hospital, Dordrecht, the Netherlands

<sup>b</sup> Department of Radiology, Albert Schweitzer Hospital, Dordrecht, the Netherlands

<sup>c</sup> Department of Biostatistics, Erasmus MC, Rotterdam, the Netherlands

<sup>d</sup> Department of Pathology, Laboratory of Pathology, Dordrecht, the Netherlands

<sup>e</sup> Regional screening organization South West the Netherlands, Maasstadweg 12, 3079 DZ, Rotterdam, The Netherlands

## ARTICLE INFO

## Article history:

Received 7 April 2020

Received in revised form

14 May 2020

Accepted 25 May 2020

Available online xxx

## Keywords:

Breast carcinoma in situ  
Magnetic resonance imaging  
Sentinel lymph node biopsy

## ABSTRACT

**Background:** In 20–25% of patients with biopsy-proven DCIS underestimation occurs. Sentinel lymph node biopsy (SLNB) is offered to patients with biopsy-proven ductal carcinoma in situ (DCIS) and a high risk of occult invasive cancer. However, assessment of high risk is controversial. We aimed to improve selection of patients for SLNB with preoperative breast magnetic resonance imaging (MRI).

**Methods:** In this prospective observational study, MRI was offered to all subsequent patients with a biopsy-proven DCIS admitted to a large Dutch teaching hospital between April 2012 and March 2017. MRI images were analysed for signs of invasive cancer and the results were compared with the pathologic results after surgical treatment. The diagnostic accuracy of additional MRI in detecting occult invasive cancer was determined.

**Results:** Of 211 patients eligible for additional MRI analysis, 149 underwent breast MRI. The majority (67%) received breast-conserving therapy, and the underestimation rate was 20%. Subsequent to MRI analysis, 20 additional invasive diagnostic procedures were performed. Occult invasive cancer was suspected on MRI in 46 patients (31%) and was confirmed in 18 (12%). In this study, breast MRI had a sensitivity of 67%, a specificity of 77%, and a true negative rate of 91%.

**Conclusion:** Preoperative breast MRI cannot reliably predict the presence of invasive cancer in patients with biopsy proven DCIS. Therefore, it cannot be used to in the selection of patients for a SLNB.

© 2020 Elsevier Ltd, BASO ~ The Association for Cancer Surgery, and the European Society of Surgical Oncology. All rights reserved.

## Introduction

Ductal carcinoma in situ (DCIS) diagnosed at core needle biopsy may represent occult invasive breast cancer. In 20–25% of patients with biopsy-proven DCIS, underestimation occurs, and invasive breast cancer is detected in the surgical specimen [1,2]. In the management of invasive breast cancer, nodal staging is standard of care, therefore several guidelines recommend the use of a sentinel lymph node biopsy (SLNB) in selected patients with a high risk of underestimation [3,4].

Underestimation has been associated with a range of factors: biopsy device and guidance method, tumor size, palpability, grade and mammographic features [1]. According to Dutch national guidelines, patients with a high risk of underestimation are defined by a high-grade DCIS on core-needle biopsy (CNB), large area (>2.5 cm) of calcifications on mammography, and age under 55 years [5]. Another reason for SLNB is a planned mastectomy (for oncologic reasons, or at patient's request) since SLNB is not feasible afterwards. After breast conserving surgery (BCS) for DCIS, a SLNB can be performed in a second procedure if pathology showed invasive cancer. Preferably, this should be anticipated on forehand. Guidelines on the use of SLNB are conflicting and sometimes vague on how to apply these risk factors to estimate high-risk DCIS. This results in a wide and undesirable hospital variation in the use of SLNB [3,4].

\* Corresponding author. Karel Lotsyweg 145, 3318, AL Dordrecht, the Netherlands.

E-mail address: [pwestenend@paldordrecht.nl](mailto:pwestenend@paldordrecht.nl) (P.J. Westenend).

<https://doi.org/10.1016/j.ejso.2020.05.028>

0748-7983/© 2020 Elsevier Ltd, BASO ~ The Association for Cancer Surgery, and the European Society of Surgical Oncology. All rights reserved.

Magnetic resonance imaging (MRI) of the breast is widely used as screening tool and as problem solving tool in the diagnostic work-up of invasive cancer. However, the possible role of MRI as problem solving tool in detecting occult invasive cancer in patients with biopsy-proven DCIS has not yet been clearly established. Limited data suggest that MRI may be a helpful addition for determining appropriate treatment [6,7].

Therefore, this study evaluated the possible role of preoperative breast MRI to detect occult invasive cancer in these patients and thereby improve the selection for a SLNB.

## Methods

### Study design

The study was a prospective observational study performed at a large teaching hospital (up to four hundred treated new cases of breast cancer per year) in the Netherlands. MRI was offered in addition to the standard treatment to all subsequent patients who received a biopsy diagnosis DCIS between April 2012 and March 2017. The Medical Ethical Board of the Maasstad hospital, Rotterdam, approved the study (protocol 2011/35).

Patients were referred via the national screening program or by their general practitioner. Each patient received the standard diagnostic work-up for suspect breast lesions. This work-up consisted of physical breast examination, digital mammography, ultrasound examination of the breast and, if necessary, also axilla. Image-guided (Affirm® Prone Breast Biopsy System Hologic) core needle biopsies were obtained with a 9G needle (Suros®) from the suspect lesions. An ultrasound-guided fine needle aspiration of the axilla was performed from those axillary lymph nodes that demonstrated focal or global cortical thickening or lacked a normal architecture.

SLNB was offered to selected patients according to Dutch guidelines, i.e. to patients with proven high-grade DCIS, an area >2.5 cm of calcifications, age <55 years, and those who were scheduled to undergo a mastectomy.

DCIS size was the size mentioned in the final pathology record. In case of multiple operations, the maximum size was calculated as the sum of the size of the primary operation and of all re-excisions.

### Patient selection

Women were included in case of a biopsy diagnosis DCIS and age >25 years. A pre-operative MRI was offered to all patients. Based on the patients' decisions, two groups were formed: 1) a non-MRI group, which included all the patients who chose not to undergo an MRI, and 2) an MRI group, including all the patients who chose to undergo an MRI.

Patients were excluded from the study in case of biopsy-proven invasive carcinoma in the same breast, or if no operative treatment was performed. In case of surgical treatment elsewhere, patients were included and the pathology results of the operation specimen were checked in the national registry of histopathology and cytopathology.

Patients were also excluded from MRI in case of claustrophobia, obesity (too large to fit into the gantry), large cup size (too large to fit into the coil), pacemaker, known inflammatory disease (such as rheumatoid arthritis, SLE, sarcoidosis or psoriasis), pregnancy, or renal failure.

Patient-related variables were gathered from the electronic medical records of our institutional database, including age, referrer, imaging, biopsy, MRI and operation details.

### Magnetic resonance imaging

MRI imaging was performed after obtaining a patient's written informed consent to participate in the study. Patients were placed in prone position in a dedicated phased-array breast coil. The MR examination protocol included 1.5-T magnet strength (Philips, Best, The Netherlands) in the following sequences: Transversal T1-weighted TSE (repetition time msec/echo time msec shortest/ 8; matrix, 512 x 512), transversal ST2W SPAIR (repetition time msec/echo time msec, 3000–5000/ 80; matrix, 512 x 512), dynamic post-contrast transversal THRIVERHR (repetition time msec/echo time msec, shortest/shortest; flip angle 10°, matrix, 256 x 256), static post-contrast transversal THRIVEHR (repetition time msec/echo time msec, shortest/shortest; flip angle 10°, matrix, 480 x 480) Field of view was restricted to 16–18 cm over the breast depending on patient size, and sections were 3 mm thick or less. T1-weighted images were acquired prior to and immediately following bolus injection of contrast-enhanced material (0.1 mmol/kg gadolinium [0.1 mmol/kg = 0.2 ml/kg] gadolinium). After intravenous injection of Gadolinium, the kinetics of the enhancement of breast tissue were studied, including construction of time intensity curves of the enhancement, using a software package of Terarecon®.

All MRI images were analysed and interpreted by one dedicated breast radiologist without knowledge of histopathologic results. In case of doubt, the radiologist reviewed the case again in consensus with a second dedicated breast radiologist (all with more than 20 years of experience in the field of breast imaging). The conclusion of the MRI report was based on morphology, kinetic curves, and contrast with surrounding tissue. The contralateral breast was analysed for anomalies. If necessary, additional diagnostics were performed based on the MRI report. These lesions prompting additional diagnostic tests were all qualified BI-RADS 3 or higher. Additional diagnostic tests consisted of additional target ultrasound of the additional lesions, and if it was found subsequent ultrasound guided biopsy was performed. If an additional lesion could not be found at ultrasound, additional MRI-guided biopsy was performed. All additional diagnostic tests were performed within one week after the initial MRI was performed.

### Diagnostic accuracy

To assess the value of the additional MRI, results of the pathological examination of the surgical specimen were regarded as the gold standard. The pathologists were blinded for the MRI results which were stored in a different electronic file system. Small specimen up to 30 g were totally embedded in paraffin. For larger specimen selection of tissue blocks for microscopic examination was based on visual inspection and specimen radiography. Slides were reviewed by pathologists with at least 20 years of experience. These results were compared with the MRI results to calculate sensitivity, specificity, true negative rate (TNR), positive predictive value (PPV) and negative predictive value (NPV). The diagnostic accuracy was additionally analysed by comparing non-high-grade DCIS (DCIS grade I and II) to high-grade DCIS (DCIS grade III) based on the pre-operative biopsy reports.

### Statistical analysis

Patient demographics and biopsy characteristics were analysed using descriptive analyses, presented as means with standard deviations, or numbers with percentages. Differences in patient demographics and in operation variables between the non-MRI group and the MRI group were identified with univariate analysis using a chi-square test or an independent samples *t*-test.

A ROC curve was composed based on the sensitivity and the

false positive rate (1 – specificity). MRI results could be classified as 1) ‘no invasive cancer’, 2) ‘invasive cancer unlikely’, 3) ‘invasive cancer likely to be present’, or 4) ‘invasive cancer present’. In current clinical practice, MRI results 1 and 2 are classified as negative test results, and MRI results 3 and 4 are classified as positive test results. To assess whether an alternative cut-off might yield a better balance of harms and benefits, sensitivity, specificity, and NPV values were calculated with different values as cut-off for a positive MRI result. Cut-off 1 represents MRI result 1 as negative test result and MRI result 2, 3 and 4 as positive test results, cut-off 2 represents the current clinical setting, and cut-off 3 represents MRI result 1, 2 and 3 as negative test results and MRI result 4 as positive test result.

For all test characteristics, binomial proportion confidence intervals of the test characteristics were calculated with the Agresti-Coull method. No imputations were made for missing data. Two-sided p-values of  $p < 0.05$  were considered statistically significant. All statistical analyses were performed using the statistical software IBM SPSS version 24.

## Results

### Patient population

In total, 211 patients with a biopsy-proven DCIS were identified as eligible for subsequent breast MRI analysis between April 2012 and March 2017 (Fig. 1). Of these patients, 62 (29%) chose not to undergo an MRI. Patients in the non-MRI group had a mean age of  $60.5 \pm 10.9$  years, and 63% of them were referred via the national screening program. Eight patients (13%) had a history of breast cancer, the majority of the patients had calcifications on mammogram (87%), and 53% of the patients had a DCIS grade III diagnosis. Patients in the MRI group (71%) had a mean age of  $57.4 \pm 9.3$  years, and 60% of them were referred via the national screening program. Twelve patients (8%) had a history of breast cancer, the majority of the patients had calcifications on mammogram (95%), and 61% of

the patients had a DCIS grade III diagnosis. Patients in the MRI group were significantly younger than those in the non-MRI group. Besides age, no statistically significant differences were found between the two groups with respect to patient demographics (Table 1).

In the non-MRI group, the primary surgical treatment was in most cases a BCS (63%) and SLNB was ultimately performed in 43 (69%) patients. Invasive cancer was detected in 26%, and 10% had involved surgical margins. In the MRI group, 68% of the patients were primarily treated with a BCS, and SLNB was ultimately performed in 108 (72%) patients. Invasive cancer was present in 18%, and 5% had involved surgical margins. In both groups, one patient had a bilateral mastectomy due to a synchronous invasive carcinoma (contralateral to DCIS). No prophylactic contralateral mastectomies were performed. The conversion rate to mastectomy was 6% in the MRI group and 11% in the non-MRI group. The size of the lesion in the surgical specimen differed significantly between the MRI and non-MRI group. Besides the size of the lesion, no statistically significant differences were found between the two groups with respect to operation characteristics (Table 1).

Preoperative breast MRI was completed in 150 patients. The mean lesion size was  $33.7 \pm 24.9$  mm. The majority of the patients (71%) had a type 1 enhancement curve, and 31% had an invasive component on MRI. Analysis of the MRI findings led to additional diagnostics of 28 lesions (in 26 patients (17%)), 20 of whom underwent an invasive procedure (See Table 2 for more details). Of all cases with invasive additional diagnostics, five patients showed extended DCIS and one patient was diagnosed with invasive carcinoma. In these cases, BCS was not possible anymore and planned treatment was changed into mastectomy.

### Diagnostic accuracy

Of the 149 patients who received a breast MRI, 27 had an invasive carcinoma in the surgical specimen and 122 had only DCIS

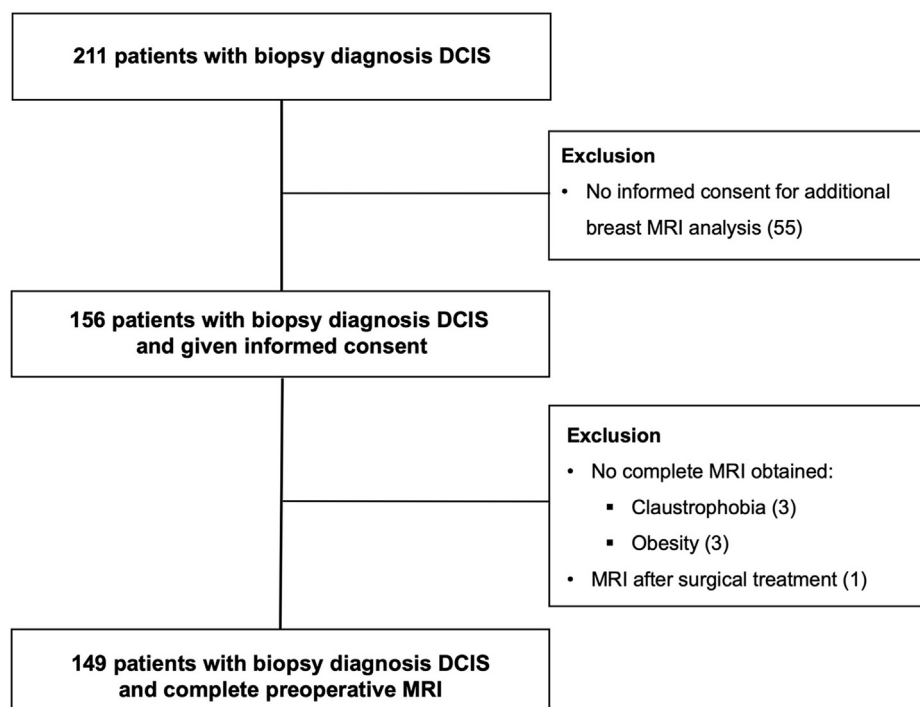


Fig. 1. Patient selection for patients with biopsy-proven DCIS.

**Table 1**  
Patient demographics of 211 patients with biopsy-proven DCIS.

	No pre-operative MRI (n = 62)	Pre-operative MRI (n = 149)	p-value
<b>Mean age ± sd, years</b>	60.5 ± 10.9	57.4 ± 9.3	<b>0.036</b>
<b>Referrer</b>	39 (63%)	90 (60%)	0.804
Screening program	13 (21%)	36 (24%)	
General practitioner	10 (16%)	22 (15%)	
Follow up Specialist		1 (1%)	
<b>History of breast pathology</b>	49 (79%)	127 (85%)	0.512
No	8 (13%)	12 (8%)	
Yes, malignant	5 (8%)	10 (7%)	
Yes, Benign			
<b>Palpable lesion</b>	48 (77%)	121 (81%)	0.530
No	14 (23%)	28 (19%)	
Yes			
<b>Calcifications</b>	8 (13%)	8 (5%)	0.084
Absent Present	54 (87%)	141 (95%)	
<b>Mass</b>	43 (69%)	115 (77%)	0.232
Absent Present	19 (31%)	34 (23%)	
<b>Density mammogram</b>	4 (7%)	3 (2%)	0.425
ACR 1	32 (53%)	78 (53%)	
ACR 2	17 (28%)	48 (32%)	
ACR 3	7 (12%)	19 (13%)	
ACR 4			
<b>BI-RADS</b>	53 (85%)	1 (1%)	0.215
BI-RADS 3	9 (15%)	137 (92%)	
BI-RADS 4		11 (7%)	
BI-RADS 5			
<b>DCIS</b>	13 (21%)	24 (16%)	0.545
Grade I	16 (26%)	34 (23%)	
Grade II	33 (53%)	91 (61%)	
Grade III			
<b>Surgical treatment</b>	39 (63%)	102 (68%)	0.435
BCS	23 (37%)	47 (32%)	
Mastectomy			
<b>SLNB</b>	20 (32%)	45 (30%)	0.768
No	42 (68%)	104 (70%)	
Yes			
<b>Histopathologic result SLNB</b>	39 (95%)	101 (97%)	0.622
Negative	2 (5%)	3 (3%)	
Positive			
<b>Surgical margins</b>	6 (10.3%)	8 (5%)	0.321
Extensive involvement	8 (14%)	14 (10%)	
Focal involvement	44 (76%)	122 (84%)	
Free			
<b>Invasive cancer</b>	46 (74%)	122 (82%)	0.207
Absent Present	16 (26%)	27 (18%)	
<b>Size lesion, mean ± sd, mm</b>	34.7 ± 32.3	26.2 ± 23.3	<b>0.050</b>
<b>Pathology diagnosis</b>	5 (8%)	9 (6%)	0.321
No invasive or in situ cancer	41 (66%)	113 (76%)	
DCIS	13 (21%)	26 (17%)	
DCIS + carcinoma	3 (5%)	1 (1%)	
Carcinoma			
<b>Additional surgical treatment</b>	52 (84%)	130 (87%)	0.516
No	10 (16%)	19 (13%)	
Yes			
<b>Specification additional surgical treatment</b>	3 (5%)	10 (7%)	0.597
BCS	5 (8%)	7 (5%)	
Mastectomy	2 (3%)	2 (1%)	
BCS + mastectomy			
<b>Additional SLNB</b>	19 (95%)	41 (91%)	1.000
No	1 (5%)	4 (9%)	
Yes			
<b>Histopathologic result additional SLNB</b>	1 (100%)	4 (100%)	
Negative			
Positive			

or no residual DCIS in the surgical specimen. In current clinical practice, additional breast MRI has a sensitivity of 67% (95%CI [47.7–81.5]), a specificity of 77% (95%CI [68.8–83.7]), and a TNR of 91% (95%CI [84.0–95.5]). Table 3 and Fig. 2 present sensitivity, specificity, and NPV values if another category is used as cut-off with an area under the curve (AUC) of 0.73 (95%CI [0.62–0.85]).

In preoperative screening, 58 of the 149 patients in the MRI group were diagnosed with non-high-grade DCIS and 92 with high-

grade DCIS. In case of non-high-grade DCIS, preoperative breast MRI had a sensitivity of 50% (95%CI [25.4–74.6]), a specificity of 91% (95%CI [79.1–97.1]), a PPV of 60% (95%CI 31.2–83.3), and a NPV of 88% (95%CI [74.9–94.5]). In case of high-grade DCIS, preoperative breast MRI had a sensitivity of 80% (95%CI [54.1–93.7]), a specificity of 68% (95%CI [57.3–78.8]), a PPV of 33% (95%CI [20.1–49.8]), and a NPV of 95% (95%CI [84.6–98.7]).

**Table 2**  
MRI characteristics of 149 patients with biopsy-proven DCIS.

	n	Percentage (%)
<b>Mean size lesion (mm)</b>		33.7 ± 24.9
<b>Enhancement curves</b>	4	3
Type 0	105	71
Type 1	12	8
Type 2	28	19
Type 3		
<b>Invasive cancer</b>	103	69
No	46	31
Yes		
<b>Additional diagnostics</b>	121	81
No	26	19
Yes		
<b>Specifications additional diagnostics</b>	6	4
Ipsilateral side - imaging only	14	11
Ipsilateral side - biopsy	2	1
Contralateral side - imaging only	6	5
Contralateral side - biopsy		
<b>Pathology results additional biopsy</b>	11	48
Ipsilateral side - benign	5	22
Ipsilateral side - malignant	6	30
Contralateral side - benign	0	
Contralateral side - malignant		

## Discussion

Underestimation of DCIS poses challenges for determining surgical management: in case of a high risk of occult invasive cancer, a sentinel lymph node biopsy can be considered. Preoperative breast MRI in patients with biopsy-proven DCIS may be a valuable additional tool for estimating the risk of occult invasive cancer. However, the added value of MRI in the diagnostic work-up has not been clearly established yet. This prospective observational study aimed to determine the clinical value of MRI in the preoperative detection of invasive cancer in patients with biopsy diagnosis DCIS. We found that MRI had a sensitivity of 67%, a specificity of 78%, and a TNR of 91%. Nuclear grade did affect sensitivity. However, for high-grade DCIS, the sensitivity was only 80%. Preoperative breast MRI did not affect the underestimation rate ( $p = 0.207$ ). Moreover, the use of MRI did not affect the mastectomy rate nor the re-operation rate. This re-operation rate is in line with a Dutch population based study on preoperative MRI in women with invasive cancer or DCIS [8].

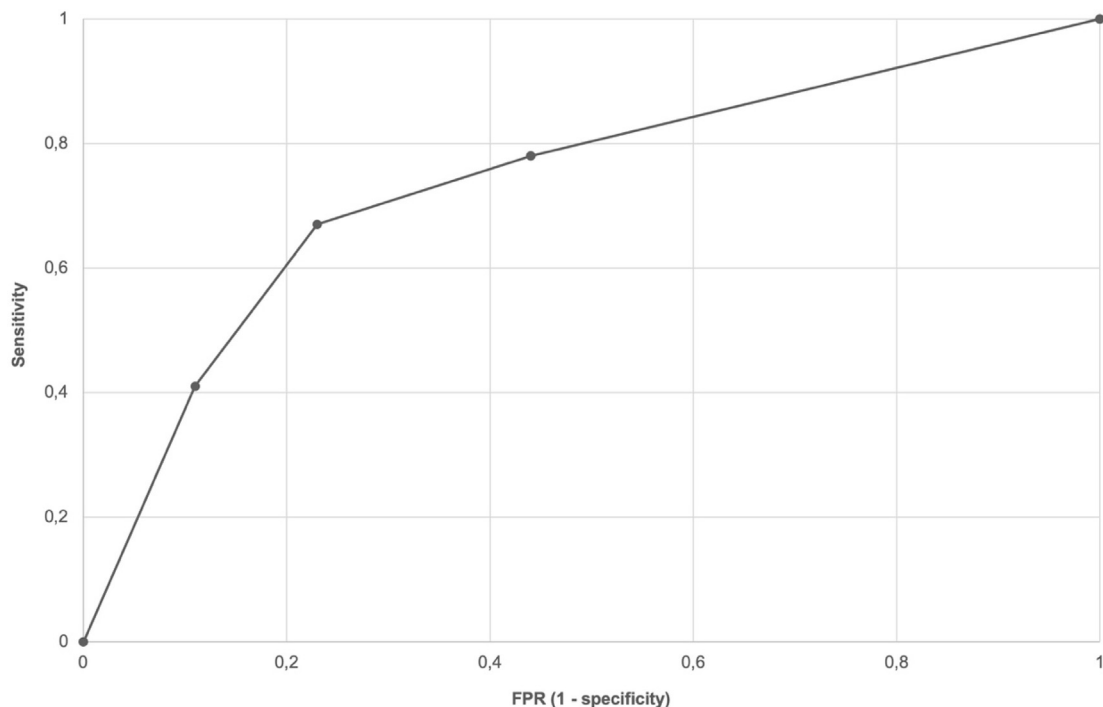
To our knowledge, this is the first prospective study focusing on preoperative breast MRI for the detection of occult invasive cancer in patients with biopsy-proven DCIS. A limited number of studies have addressed the effect of MRI on the detection of occult breast cancer in patients with biopsy-proven DCIS, [9–16], but most of

**Table 3**  
Diagnostic accuracy with multiple cut-off values for positive MRI result.

	n = MRI + / SR +	n = MRI - / SR -	Sensitivity (95% CI)	Specificity (95% CI)	TNR (95% CI)
Cut-off 1 (MRI-finding 1 (-) vs 2,3& 4 (+))	21	68	78% (58.9–89.7)	56% (46.9–64.2)	92% (83.1–96.5)
Cut-off 2 (MRI-finding 1&2 (-) vs 3& 4 (+))	18	94	67% (47.7–81.5)	77% (68.8–83.7)	91% (84.0–95.5)
Cut-off 3 (MRI-finding 1,2&3 (-) vs 4 (+))	11	108	41% (24.5–59.3)	89% (81.5–93.2)	87% (80.0–92.0)

SR = (histopathologic result) surgical resection; Total positive results SR = 27, total negative results SR = 122.

MRI-findings: 1) 'no invasive cancer'; 2) 'invasive cancer unlikely'; 3) 'invasive cancer likely to be present'; 4) 'invasive cancer present'.



**Fig. 2.** ROC curve of the MRI result using the pathological examination as the gold standard.



these studies were small and retrospective and therefore the inclusion of patients was based on the availability of MRI data of these patients. The large differences in underestimate rates, from 14 to 55%, indicate the likelihood of bias in these studies [9–16]. In most of these studies, the underestimation rate was between 20 and 25%, which is in line with the underestimation rate of 20% that we found [1,2]. As far as we know, the only other prospective study is a study by Deurloo et al., but it is not clear how patients in that study were selected for MRI [11].

Our finding that preoperative MRI has a NPV of 95% in case of high-grade DCIS suggests that MRI can be of value in excluding the presence of occult breast cancer. This is in line with the findings of Deurloo et al., who also concluded that MRI is especially valuable in excluding the presence of occult breast cancer [11].

On the other hand, our finding that the sensitivity of MRI is too low to be of use in identifying patients with occult breast cancer is in contrast with several studies that concluded that it is possible to use MRI to detect some of the occult breast cancers, without attempting to determine the sensitivity of MRI in doing this [9,12,13,15,16]. In studies of Goto et al. and Harowitz et al., the sensitivity of MRI was presented as ROC curves with an AUC of 0.71 and 0.719, respectively, [10,14], which is in line with our finding of an AUC of 0.73. However, Goto et al. nevertheless concluded that MRI is potentially useful, without clearly specifying how [10]. Harowitz et al. arrived at a firmer conclusion and stated that MRI can be used to identify patients at the highest risk of occult breast cancer [14].

The impact of preoperative MRI for DCIS on re-intervention rates remains controversial [17]. Some studies claimed that MRI allowed for a more accurate determination of the extent of disease without reporting on re-intervention rates, [13,18,19], and some others also reported a lower re-intervention rate [20,21]. However, some of the larger studies did not find lower re-excision rates [8,22–24]. A study by So et al. could not find an effect on the number of cavity shavings to obtain a free margin [25]. Our study could also not advocate preoperative MRI as a means to plan BC based on re-intervention rates, since we found no differences in re-operation rates between the MRI group and non-MRI group.

A widely held concern regarding the use of preoperative MRI in diagnostic work-up for DCIS is the supposed risk of a subsequent increase of mastectomies. We found that MRI did not result in higher mastectomy rates, which is in line with some studies that also reported no effect of MRI on mastectomy rates [21,23]. By contrast, the majority of the studies on the effect of MRI on mastectomy rates reported an increased rate [8,20,22,24,26]. Differences between these studies are hard to explain but are probably related to the radiologists' interpretations of the MRI images.

Another concern regarding preoperative MRI for DCIS is the assumed subsequent increase of additional biopsies [27]. In the current study, additional biopsies were performed of 20 lesions, and only six of these biopsies demonstrated the presence of additional ipsilateral disease (5 DCIS, and 1 invasive carcinoma). No contralateral malignancies were detected. Although in the current study, MRI only resulted in detecting additional cancers in 4% of the included patients, previously published numbers about additional biopsies ranged from 3 to 30% [20–23,28]. Benveniste et al. studied in detail the additional or invasive sites of disease detected by means of MRI after diagnosis of pure DCIS. Additional biopsies were performed in 30% of the patients, and 26% of these extra biopsies led to diagnoses of additional or invasive sites of disease. In contrast to our study, Benveniste et al. only detected contralateral additional or invasive sites of disease [28].

This study has several limitations. First of all, it was a single center study that did not randomize patients between MRI or no MRI. Fortunately, we were able to include all the patients that did

not want to receive preoperative MRI in our analysis. No differences in patient characteristics were found except that the mean age was slightly higher in the non-MRI group. A decline in MRI rate with increasing age is in line with the results of Tuttle et al. [29]. Therefore, we assume that this cohort is representative and that the risk of selection bias is negligible. Another limitation is that the coil that was placed to mark the biopsy site may have resulted in artefacts, which sometimes makes the evaluation of MRI images challenging. Besides, suspect lesions may have been small and may have had the same size as the biopsy needles that were used. Consequently, all suspect tissue was removed in those cases, and MRI resulted in post-biopsy images with normal background tissue. However, in case of significantly extended disease, MRI should have been able to detect these lesions. The area around the coil where artefacts may occur is small, 3–5 mm, but in some cases this equals the area of the initial calcifications. Therefore, evaluation of the remaining breast tissue was still feasible. Besides, post-biopsy but preoperative MRI is based on current clinical practice, which makes these data applicable to daily practice.

Although improvement of diagnostic performance was seen in patients with high-grade DCIS, unfortunately the overall sensitivity of MRI remained poor. Our results and the diverging results of previous studies highlight the difficulty of interpreting MRI in case of DCIS. Consequently, assessment of DCIS with MRI is not the answer to assess the risk of occult invasive cancer and thereby improve the selection of patients for a SLNB.

## Conclusion

In patients with biopsy-proven DCIS, negative MRI could reliably identify patients without invasive breast cancer. However, additional preoperative breast MRI cannot reliably predict the presence of invasive cancer in patients with pure DCIS. Therefore, preoperative breast MRI in patients with biopsy proven DCIS cannot be used in the selection of patients for a SLNB.

## Funding

This study was sponsored by a grant of Pink Ribbon, the Netherlands.

## Role of the funding source

This study was sponsored by a grant of Pink Ribbon, the Netherlands. The sponsor was only involved in the financial support to perform the additional MRI's. The sponsor was not involved in the content of the study.

## CRediT authorship contribution statement

**Sara van Bekkm:** Funding acquisition, Writing - review & editing. **Bert P.M. ter Braak:** Conceptualization, Funding acquisition, Formal analysis, Writing - review & editing. **Peter W. Plaisier:** Conceptualization, Formal analysis, Writing - review & editing. **Joost van Rosmalen:** Formal analysis, Writing - review & editing. **Marian B.E. Menke-Pluijmers:** Formal analysis, Writing - review & editing. **Pieter J. Westenend:** Conceptualization, Funding acquisition, Formal analysis, Writing - review & editing.

## Declaration of competing interest

The authors of this manuscript declare no relationships with any companies, whose products or services may be related to the subject matter of the article.

## References

- [1] Brennan ME, Turner RM, Ciatto S, et al. Ductal carcinoma in situ at core-needle biopsy: meta-analysis of underestimation and predictors of invasive breast cancer. *Radiology* 2011;260(1):119–28.
- [2] Meurs CJ, van Rosmalen J, Menke-Pluijmers MBE, et al. A prediction model for underestimation of invasive breast cancer after a biopsy diagnosis of ductal carcinoma in situ: based on 2892 biopsies and 589 invasive cancers. *Br J Canc* 2018;119:1155–62.
- [3] Holm-Rasmussen EV, Jensen MB, Balslev E, Kroman N, Tvedskov TF. The use of sentinel lymph node biopsy in the treatment of breast ductal carcinoma in situ: a Danish population-based study. *Eur J Canc* 2017;87(2017):1–9.
- [4] Mitchell KB, Lin H, Shen Y, et al. DCIS and axillary nodal evaluation: compliance with national guidelines. *BMC Surg* 2017;17(1):12.
- [5] Richtlijn mammacarcinoom. <https://richtlijndatabase.nl/richtlijn/borstkanker>.
- [6] Bluemke D a, Gatsonis C a, Chen MH, et al. Magnetic resonance imaging of the breast prior to biopsy. *J Am Med Assoc* 2004;292:2779–80.
- [7] Kuhl CK, Schrading S, Bieling HB, et al. MRI for diagnosis of pure ductal carcinoma in situ: a prospective observational study. *Lancet* 2007;370:485–92.
- [8] Vos EL, Voogd AC, Verhoef C, Siesling S, Obdeijn IM, Koppert LB. Benefits of preoperative MRI in breast cancer surgery studied in a large population-based cancer registry. *Br J Surg* 2015;102(13):1649–57.
- [9] Hwang ES, Kinkel K, Esserman LJ, Lu Y, Weidner N, Hylton NM. Magnetic resonance imaging in patients diagnosed with ductal carcinoma-in-situ: value in the diagnosis of residual disease, occult invasion, and multicentricity. *Ann Surg Oncol* 2003;10(4):381–8.
- [10] Goto M, Yuen S, Akazawa K, et al. The role of breast MR imaging in preoperative determination of invasive disease for ductal carcinoma in situ diagnosed by needle biopsy. *Eur Radiol* 2012;22(6):1255–64.
- [11] Deurloo EE, Sriram JD, Teertstra HJ, et al. MRI of the breast in patients with DCIS to exclude the presence of invasive disease. *Eur Radiol* 2012;22(7):1504–11.
- [12] Miyashita M, Amano G, Ishida T, et al. The clinical significance of breast MRI in the management of ductal carcinoma in situ diagnosed on needle biopsy. *Jpn J Clin Oncol* 2013;43(6):654–63.
- [13] Petrillo A, Fusco R, Petrillo M, et al. Added value of breast MRI for preoperative diagnosis of ductal carcinoma in situ: diagnostic performance on 362 patients. *Clin Breast Canc* 2017;17(3):127–34.
- [14] Harowicz MR, Saha A, Grimm LJ, et al. Can algorithmically assessed MRI features predict which patients with a preoperative diagnosis of ductal carcinoma in situ are upstaged to invasive breast cancer? *J Magn Reson Imag* 2017;46(5):1332–40.
- [15] Wisner DJ, Hwang ES, Chang CB, et al. Features of occult invasion in biopsy-proven DCIS at breast MRI. *Breast J* 2013;19(6):650–8.
- [16] Lee CW, Wu HK, Lai HW, et al. Preoperative clinicopathologic factors and breast magnetic resonance imaging features can predict ductal carcinoma in situ with invasive components. *Eur J Radiol* 2016;85:780–9.
- [17] Park TS, Hwang ES. Current trends in the management of ductal carcinoma in situ. *Rev Artic Oncol J Breast Cancer* 2016;23(1).
- [18] Baur A, Bahrs SD, Speck S, et al. Breast MRI of pure ductal carcinoma in situ: sensitivity of diagnosis and influence of lesion characteristics. *Eur J Radiol* 2013;82:1731–7.
- [19] Proulx F, Correa JA, Ferre R, et al. Value of pre-operative breast MRI for the size assessment of ductal carcinoma in situ. *Br J Radiol* 2016;89.
- [20] Hajaj M, Karim A, Pascaline S, Noor L, Patel S, Dakka M. Impact of MRI on high grade Ductal Carcinoma In situ (HG DCIS) management, are we using the full scope of MRI? *Eur J Radiol* 2017;95:271–7.
- [21] Lam DL, Smith J, Partridge SC, et al. The impact of preoperative breast MRI on surgical management of women with newly diagnosed ductal carcinoma in situ. *Acad Radiol* 2019;27(4):478–86.
- [22] Itakura K, Lessing J, Sakata T, et al. The impact of preoperative magnetic resonance imaging on surgical treatment and outcomes for ductal carcinoma in situ. *Clin Breast Canc* 2011;11(1):33–8.
- [23] Balleyguier C, Dunant A, Ceugnart L, et al. Preoperative breast magnetic resonance imaging in women with local ductal carcinoma in situ to optimize surgical outcomes: results from the randomized phase III trial IRCIS. *J Clin Oncol* 2019;37(11):885–92.
- [24] Keymeulen KBIM, Geurts SME, Lobbes MBI, et al. Population-based study of the effect of preoperative breast MRI on the surgical management of ductal carcinoma in situ. *Br J Surg* 2019;106(11):1488–94.
- [25] So A, De La Cruz LM, Williams AD, et al. The impact of preoperative magnetic resonance imaging and lumpectomy cavity shavings on re-excision rate in pure ductal carcinoma in situ—a single institution's experience. *J Surg Oncol* 2018;117:558–66.
- [26] Sheaffer WW, Gray RJ, Wasif N, et al. Predictive factors of upstaging DCIS to invasive carcinoma in BCT vs mastectomy. *Am J Surg* 2019;217(6):1025–9.
- [27] Pilewskie M, Kennedy C, Shappell C, et al. Effect of MRI on the management of ductal carcinoma in situ of the breast. *Ann Surg Oncol* 2013;20(5):1522–9.
- [28] Benveniste AP, Perez TO, Ebuoma LO, et al. Is breast magnetic resonance imaging (MRI) useful for diagnosis of additional sites of disease in patients recently diagnosed with pure ductal carcinoma in situ (DCIS)? *Eur J Radiol* 2017;74–9.
- [29] Tuttle TM, Jarosek S, Durham S, Virnig BA. Use of preoperative breast MRI data points # 13. *Points D*; 2012.