

No Evidence of Varicella-Zoster Virus Infection in Temporal Artery Biopsies of Anterior Ischemic Optic Neuropathy Patients With and Without Giant Cell Arteritis

Robert M. Verdijk,^{1,2} Werner J. D. Ouwendijk,³ Robert W. A. M. Kuijpers,^{4,5,6} and Georges M. G. M. Verjans³

¹Department of Pathology, Section Ophthalmic Pathology, Erasmus Medical Center (MC) University Medical Center Rotterdam, Rotterdam, The Netherlands, ²Department of Pathology, Leiden University Medical Center, Leiden, The Netherlands, ³Department of Viroscience, Erasmus MC University Medical Center Rotterdam, Rotterdam, The Netherlands, ⁴Department of Ophthalmology, Albert Schweitzer Hospital, Dordrecht, The Netherlands, ⁵Department of Ophthalmology, Erasmus MC University Medical Center Rotterdam, Rotterdam, The Netherlands, ⁶Department of Ophthalmology, Universitair Ziekenhuis Brussel, Vrije Universiteit Brussel, Brussels, Belgium

Background. To test the hypothesis that varicella-zoster virus (VZV) infection contributes to temporal arteritis pathogenesis, comprehensive *in situ* analysis was performed on temporal artery biopsies of 38 anterior ischemic optic neuropathy (AION) patients, including 14 (37%) with giant cell arteritis.

Methods. Biopsies were completely sectioned, and, on average, 146 serial sections per patient were stained for VZV glycoprotein E.

Results. Four of 38 AION patients showed VZV glycoprotein E staining, but VZV infection was not confirmed by staining for VZV IE63 protein and VZV-specific polymerase chain reaction on adjacent sections.

Conclusions. This study refutes the premise that VZV is casually related to AION with and without giant cell arteritis.

Keywords. anterior ischemic optic neuropathy; giant cell arteritis; immunohistochemistry nonspecific staining; temporal arterial biopsies; varicella-zoster virus.

Ischemic optic neuropathy is a sight-threatening disease that generally affects the optic nerve head (anterior ischemic optic neuropathy [AION]) [1]. Anterior ischemic optic neuropathy is the most common cause of acute optic nerve damage in individuals >50 years old, with an annual incidence of 2–10 cases per

100 000 persons. The vast majority of AION cases are idiopathic, but some specific etiologies reported are optic disc drusen, sleep apnea syndrome, medication, and general vascular risk factors [1]. The disease is typically divided into patients with and without vasculitis, usually giant cell arteritis (GCA) based on clinical symptoms such as headache and jaw claudication. Prompt diagnosis of arteritic AION is critical, because GCA may cause irreversible ischemic damage to the fellow eye, brain, and even the heart [1, 2]. A temporal artery biopsy (TAB) with mononuclear cell infiltrate and granulomatous inflammation is considered the gold standard for GCA diagnosis [1, 2].

Giant cell arteritis is an alleged, antigen-driven inflammation of medium to large arteries with several genetic and epidemiologic features suggesting a connection to an infectious agent [2, 3]. Multiple hypotheses are being pursued, including one raised more recently in which varicella-zoster virus (VZV) infection of the arteries contributes to the inflammatory cascade [2–5]. Initial studies described widespread presence of VZV protein and/or deoxyribonucleic acid (DNA) in the majority GCA cases, as well as in TABs from patients with clinically suspected GCA but pathologically negative biopsy results [4, 5]. However, subsequent reports by other groups could not replicate these findings [3, 6–11]. Discrepancies may be due to the VZV antigen assayed, VZV glycoprotein E (VZV-gE) was commonly assayed in earlier studies showing strong VZV-GCA association, and the relative low number of sections stained per TAB [4, 5]. Indeed, similar to GCA pathophysiology [2], VZV infection may be focal and therefore requires detailed *in situ* analysis of a large number of serial sections spanning most of the TAB [3–5].

The aim of our retrospective study was to support or refute the VZV-AION, and particularly the GCA-VZV association, by performing well standardized immunohistochemistry (IHC), including the use of tissue microarrays (TMAs) with automated IHC targeting VZV-gE expression in large numbers of consecutive sections of 38 AION cases. Positive VZV-gE stainings, indicative for VZV infection, were corroborated by IHC and real-time polymerase chain reaction (PCR) analysis for detection of VZV immediate-early protein 63 (VZV-IE63) and VZV DNA in adjacent TAB sections, respectively.

METHODS

Specimens

Formalin-fixed and paraffin-embedded (FFPE) temporal artery biopsies obtained for diagnostic purposes of 38 AION patients, treated on suspicion of temporal arteritis between 1988 and 2014 at the Department of Ophthalmology of Erasmus Medical Center (EMC) and Rotterdam Eye Hospital (both in Rotterdam,

Received 25 May 2020; editorial decision 16 July 2020; accepted 9 September 2020; published online September 9, 2020.

Correspondence: Georges M. G. M. Verjans, MSc, PhD, Department of Viroscience, Erasmus MC University Medical Center Rotterdam, P.O. Box 2040, 3000 CA, Rotterdam, The Netherlands (g.verjans@erasmusmc.nl).

The Journal of Infectious Diseases® 2020;XX:1–4

© The Author(s) 2020. Published by Oxford University Press for the Infectious Diseases Society of America. This is an Open Access article distributed under the terms of the Creative Commons Attribution-NonCommercial-NoDerivs licence (<http://creativecommons.org/licenses/by-nc-nd/4.0/>), which permits non-commercial reproduction and distribution of the work, in any medium, provided the original work is not altered or transformed in any way, and that the work is properly cited. For commercial re-use, please contact journals.permissions@oup.com
DOI: 10.1093/infdis/jiaa566

The Netherlands), were provided by the EMC Tissue Bank (Supplementary Table 1). The study was performed according to the Declaration of Helsinki, and material was obtained in accordance with institutional regulations. Classic histopathological parameters, including granulomatous inflammation with giant cells and destruction of lamina elastica interna, were evaluated by routine hematoxylin/eosin and elastin staining [2, 3]. Two TMA blocks were constructed from one to four 5-mm core samples containing complete FFPE specimens of all 38 cases. Two thirds of TABs were too long and were split in 2 or even 4 parts that were all included in the TMAs (Supplementary Table 1). Approximately 215 serial 4- μ m sections were cut from each TMA block, hereby completely processing the embedded biopsies.

Immunohistochemistry

In situ analysis was performed with an automated IHC staining system (Ventana BenchMark ULTRA; Ventana Medical Systems) using the diaminobenzidine method for all mouse monoclonal antibodies (mAbs) as a brown chromogen. In brief, after deparaffinization and heat-induced antigen retrieval using Cell Conditioning Solution 1 (Ventana Medical Systems) for 64 minutes at 97°C, sections were incubated for 1 hour at 36°C with predefined concentration of VZV-gEs reactive mAb (clone MAB8612, Millipore; Chemicon, lot number 2526705, dilution 1:500). A subsequent amplification step was followed by hematoxylin-counterstain and finally Bluing Reagent according to the manufacturer's instructions (Ventana Medical Systems). Every third slide was stained for VZV-gE, hereby retaining consecutive sections for DNA isolation for VZV-specific PCR analysis or additional IHC stainings to detect VZV-IE63 (clone 9D12, dilution 1:1000 [12]; a gift from Prof. Dr. Sadzot-Delvaux, University of Liege, Liege, Belgium), CD3 (T-cell marker [clone 2GV6; Ventana]), or tryptase (mast cell marker [clone G3; Cell Marque]) [13]. Formalin-fixed and paraffin-embedded skin sections of an herpes zoster patient, obtained from the EMC Tissue Bank, were used as positive control. Positive VZV antigen staining was considered if this was observed in at least 2 serial sections stained for VZV-gE and subsequently confirmed with VZV-IE63 IHC on consecutive sections.

RESULTS

All 38 patients presented to an ophthalmologist with clinical signs of AION, 19 patients (50%) of which also developed typical vasculitic AION-associated headache. All patients met the American College of Rheumatology 1990 classification criteria for GCA [1, 2]. Mean age at presentation was 73 years (range, 45–91 years) and 23 (61%) patients were female (Supplementary Table 1).

Ten of 38 TAB (26%) showed GCA at initial histopathological evaluation. To confer standardization in both tissue processing and IHC stainings, we constructed 2 TMA blocks,

which contained core TAB specimens of all 38 AION cases, and used the Ventana BenchMark ULTRA automated IHC system to facilitate controlled in situ analysis, respectively. The mean number serial slides available for IHC per TAB was 438 (range, 216–864 sections). After careful re-examination, we identified 4 additional TABs with typical focal GCA lesions (Supplementary Table 1), which underscores and the well described low incidence of temporal arteritis in clinically suspected cases that warrants extensive sectioning of TABs [2, 3].

To detect VZV infection in TAB of 38 AION patients, every third section of each TAB section series was stained with a commercially available VZV-gE-specific mAb, which first was optimized and validated in the automated IHC system on herpes zoster FFPE skin sections, which also included healthy skin as internal control tissue (Supplementary Figure 1). In total, 5472 sections were stained for VZV-gE, with an average of 146 TAB sections (range, 72–288) per AION patient. Four of 38 TABs (10.5%), including 2 AION cases with GCA and 1 case that showed an arteritis lesion only after complete sectioning, showed focal VZV-gE^{pos} IHC staining in at least 2 consecutive sections. For 2 cases, this was localized mainly in smooth muscle cells of both arterial media and adventitial vessels in a maximum of 4 consecutive sections in a pattern similar to what has been reported positive in earlier publications (Figure 1 and Supplementary Table 1) [5–8]. Staining in myocytes appeared in a patchy distribution, and staining intensity and number of positive cells varied extensively both at the inter- and intraspecimen level. Such patchy expression may reflect a false-positive result,

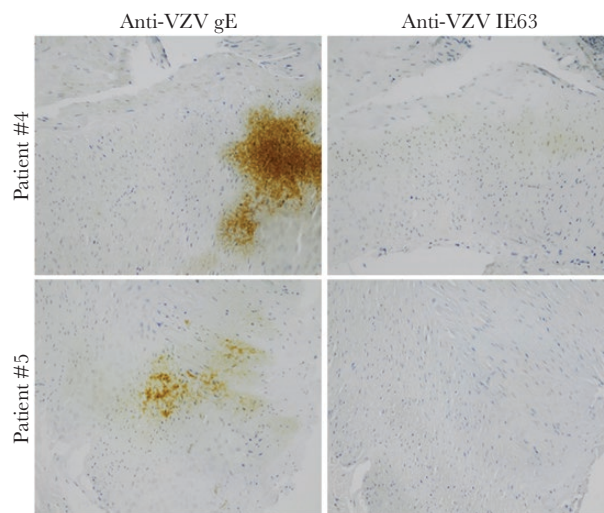


Figure 1. Immunohistochemical staining for varicella-zoster virus (VZV) protein expression in temporal arterial biopsies of 2 anterior ischemic optic neuropathy (AION) patients. Consecutive sections (4 μ m) of AION patient no. 4 (top panels) and no. 5 (bottom panels; see Supplementary Table 1) were stained with mouse monoclonal antibodies direct to VZV glycoprotein E (gE) and immediate-early protein 63 (IE63). Positive staining signals are in brown color and original magnification was $\times 100$.

potentially due to tissue dehiscence during staining, and the fact that staining was seen without surrounding inflammatory response supported this impression (Figure 1) [4, 7, 8]. We also observed apparent false-positive VZV-gE staining of spindle-like cells in the adventitial layer of 2 other TABs with dense inflammatory cell infiltrates containing mast cells (Figure 2). This second VZV-gE staining pattern was observed in all sections containing the inflammatory infiltrates.

To unequivocally confirm VZV infection in the TABs of the 4 VZV-gE^{pos} AION cases, we performed IHC on consecutive TMA sections using an anti-VZV-IE63 mAb [12]. Using this anti-VZV mAb, however, no positive VZV-IE63 staining was observed (Figure 2). Finally, we performed VZV-specific TaqMan analysis on DNA recovered from consecutive sections at the same anatomic level of the respective TABs showing positive VZV-gE IHC staining (Supporting Methods Text). Whereas the single-copy housekeeping gene HMBS was readily detected, VZV DNA could not be detected by the highly sensitive VZV-specific TaqMan assay (Supplementary Table 2). It is notable that both the VZV-IE63 and -gE IHC, and VZV- and HMBS-specific TaqMan assays, on human herpes zoster and control skin tissues showed IHC and TaqMan data as expected (Supplementary Tables 1 and 2 and Supplementary Figure 1).

DISCUSSION

Varicella-zoster virus vasculopathy and subsequently arterial ischemic stroke is hypothesized to be caused by reactivation of latent VZV in innervating neurons, followed by anterograde axonal spread and productive VZV infection of cerebral arteries,

which leads to a local inflammatory response [4–6]. Clinical signs and symptoms caused by VZV vasculopathy resemble those of AION, especially arteritic AION, suggesting an analogous role of arterial VZV infection in AION pathogenesis [1, 2]. Indeed, VZV antigen has been detected by IHC in affected arteries of GCA-negative TABs of 7 AION patients [14]. Moreover, earlier reports describing the high prevalence of VZV protein in both GCA-positive (73 of 104 cases, 70%) and -negative TABs (58 of 100 cases, 58%) and even autopsy-obtained control TABs (11 of 61 specimens, 18%) are of potential clinical relevance [4, 5], but its association is still under debate and warrants confirmation [3, 6–11].

The current study was designed to meet the criticism raised on correctly detecting VZV infection in TABs of clinically suspect cases with temporal arteritis: (1) we included TABs of 38 (non-)arteritic well defined AION cases, (2) TABs were sectioned completely for meticulous in situ analysis of which (3) every third section was stained for the abundant lytic viral VZV-gE protein (on average 146 serial sections/TAB), and (4) we performed confirmatory IHC for VZV-IE63 and VZV-specific PCR analysis on consecutive sections of suspect VZV-gE^{pos} TABs, hereby enabling a comprehensive analysis of VZV infection throughout the complete TABs [3–11]. Furthermore, we generated 2 TMAs encompassing all 38 TABs, including a herpes zoster skin lesion as positive control, facilitating controlled IHC analysis using a validated automated IHC staining system that limits inter-IHC assay variation. In our opinion, this approach is least likely to cause staining artifacts.

The VZV-gE expression in TABs of 4 of 38 AION cases suggested productive infection, which, however, could not be confirmed by IHC for VZV-IE63 and VZV-specific PCR analysis on consecutive sections. Two types of false-positive VZV-gE staining patterns were observed. The first one was a patchy VZV-gE IHC signal mainly in smooth muscle cells, of both arterial media and adventitial vessels, and no clear membrane VZV-gE staining reflecting a truly lytic VZV-infected cell was observed [3–5, 14]. Similar staining patterns have been described earlier by others and also considered false positive, especially because nonspecific antibody binding is commonly observed in smooth and skeletal muscle cells [6, 7, 10]. The second type of VZV-gE staining pattern appeared more like VZV-infected cells in situ, individual spindle-like cells with strong membranous staining, and was detected at sites of dense inflammation. Close examination of the inflammatory cell types revealed the presence of mast cells at the same location. More specifically, the VZV-gE signal frequently overlapped that of individual mast cells stained for in consecutive sections. Mast cells may contribute to temporal arteritis by stimulating the pathogenic effector functions of infiltrating inflammatory cells but also promote neovascularization [2, 3]. Nonspecific staining of mast cells by IHC is common and may involve nonspecific antibody binding to Fc receptors or heparin contained

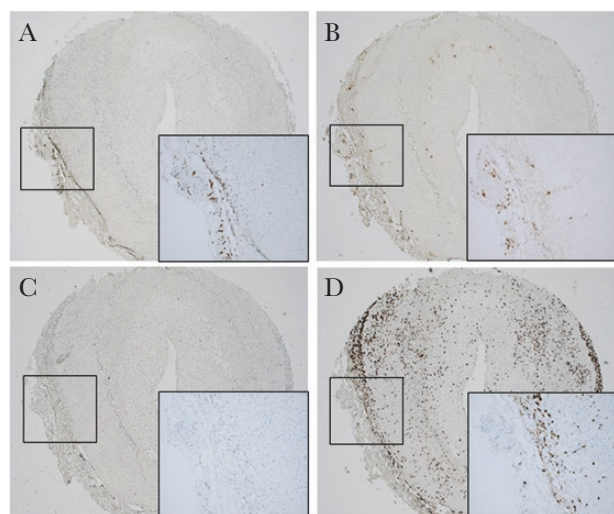


Figure 2. Immunohistochemical staining for varicella-zoster virus (VZV) protein expression in a temporal artery biopsy of an anterior ischemic optic neuropathy (AION) patient overlaps with mast cell infiltrate. Consecutive sections (4 µm) of 1 AION case (patient no. 24) were stained for VZV glycoprotein E (A), tryptase (mast cell marker [B]), VZV immediate-early protein 63 (IE63 [C]), and CD3 (T-cell marker [D]). Positive staining signals are in brown color and insets are enlargements of the boxed areas. Original magnification was $\times 50$.

within mast cell granules [15]. The Ventana detection system does not use biotin/streptavidin, ruling out endogenous biotin as a reason for nonspecific staining results [15].

CONCLUSIONS

In conclusion, this study describes a comprehensive and well controlled in situ analysis on TABs of a large cohort of AION cases that refutes the hypothesis that arterial VZV infection contributes to AION pathogenesis, both with and without GCA [2, 4]. Our data add to recent investigations from multiple laboratories worldwide (including United States, Canada, Australia, Sweden, Denmark, Spain, Italy, and United Kingdom) that all failed to reproduce the suspected association of VZV reactivation in temporal arteritis [3, 7–11]. Care in practice and interpretation of in situ methodologies are key for correct diagnosing and proving pathogenic involvement and, ultimately, to ensure correct treatment of patients with temporal arteritis including AION [1–3]. It is clear that a consensus on the association between VZV and temporal arteritis is crucial not only to determine the virus' impact on disease but also for diagnostic pathology in general [2, 3]. An international workshop involving multiple laboratories sharing materials and methods is warranted to fulfill the unmet medical need for consensus in the field.

Supplementary Data

Supplementary materials are available at *The Journal of Infectious Diseases online*. Consisting of data provided by the authors to benefit the reader, the posted materials are not copyedited and are the sole responsibility of the authors, so questions or comments should be addressed to the corresponding author.

Supplementary Figure 1. Immunohistochemical staining for VZV protein expression in a skin biopsy from a herpes zoster patient. Consecutive skin sections of a herpes zoster lesion and adjacent health skin were stained for expression of VZV glycoprotein E ([gE] A and C) and immediate-early protein 63 (IE63) (B and D), respectively. Positive staining signals are in brown color and original magnification was $\times 100$.

Notes

Potential conflicts of interest. All authors: No reported conflicts of interest. All authors have submitted the ICMJE Form for Disclosure of Potential Conflicts of Interest.

References

1. Athappilly G, Pelak VS, Mandava N, Bennett JL. Ischemic optic neuropathy. *Neurol Res* **2008**; 30:794–800.
2. Rubenstein E, Maldini C, Gonzalez-Chiappe S, Chevret S, Mahr A. Sensitivity of temporal artery biopsy in the

diagnosis of giant cell arteritis: a systematic literature review and meta-analysis. *Rheumatology (Oxford)* **2020**; 59:1011–20.

3. Ostrowski RA, Metgud S, Tehrani R, Jay WM. Varicella zoster virus in giant cell arteritis: a review of current medical literature. *Neuroophthalmology* **2019**; 43:159–70.
4. Gilden D, White T, Khmeleva N, Boyer PJ, Nagel MA. VZV in biopsy-positive and -negative giant cell arteritis: analysis of 100+ temporal arteries. *Neurol Neuroimmunol Neuroinflamm* **2016**; 3:e216.
5. Nagel MA, White T, Khmeleva N, et al. Analysis of varicella-zoster virus in temporal arteries biopsy positive and negative for giant cell arteritis. *JAMA Neurol* **2015**; 72:1281–7.
6. Buckingham EM, Foley MA, Grose C, et al. Identification of herpes zoster-associated temporal arteritis among cases of giant cell arteritis. *Am J Ophthalmol* **2018**; 187:51–60.
7. Pisapia DJ, Lavi E. VZV, temporal arteritis, and clinical practice: false positive immunohistochemical detection due to antibody cross-reactivity. *Exp Mol Pathol* **2016**; 100:114–5.
8. Muratore F, Croci S, Tamagnini I, et al. No detection of varicella-zoster virus in temporal arteries of patients with giant cell arteritis. *Semin Arthritis Rheum* **2017**; 47:235–40.
9. Solomon IH, Docken WP, Padera RF Jr. Investigating the association of giant cell arteritis with varicella zoster virus in temporal artery biopsies or ascending aortic resections. *J Rheumatol* **2019**; 46:1614–8.
10. Sammel AM, Smith S, Nguyen K, et al. Assessment for varicella zoster virus in patients newly suspected of having giant cell arteritis. *Rheumatology* **2019**:kez556. doi: [10.1093/rheumatology/kez556](https://doi.org/10.1093/rheumatology/kez556).
11. Kennedy PG, Grinfeld E, Esiri MM. Absence of detection of varicella-zoster virus DNA in temporal artery biopsies obtained from patients with giant cell arteritis. *J Neurol Sci* **2003**; 215:27–9.
12. Kennedy PG, Grinfeld E, Bontems S, Sadzot-Delvaux C. Varicella-zoster virus gene expression in latently infected rat dorsal root ganglia. *Virology* **2001**; 289:218–23.
13. Ouwendijk WJ, Flowerdew SE, Wick D, et al. Immunohistochemical detection of intra-neuronal VZV proteins in snap-frozen human ganglia is confounded by antibodies directed against blood group A1-associated antigens. *J Neurovirol* **2012**; 18:172–80.
14. Golas L, Bennett JL, White TM, et al. Varicella zoster virus in ischemic optic neuropathy. *Ophthalmology* **2015**; 122:2142–5.
15. Schiltz PM, Lieber J, Giorno RC, Claman HN. Mast cell immunohistochemistry: non-immunological immunostaining mediated by non-specific F(ab')₂-mast cell secretory granule interaction. *Histochem J* **1993**; 25:642–7.